



Lumbar radiculopathy is the clinical description of leg pain (sciatica) associated with low back pain. Radicular pain is often secondary to compression or inflammation of a spinal nerve. When the pain radiates down the back of the leg to the calf or foot, it would in lay terms be described as sciatica. This type of pain is often deep and steady and can usually be reproduced with certain activities and positions, such as sitting or walking.

The pain usually follows the involved dermatome in the leg - the area of distribution of the leg covered by the specific nerve. When a nerve at the L4-5 or L5-S1 level is affected (bottom two levels), this dermatome is usually the sciatic nerve, which runs down the back of each leg to the foot.

Sciatica, the term commonly used to describe radicular pain along the sciatic nerve, describes where the pain is felt but is not an actual diagnosis. The clinical diagnosis is usually arrived at through a combination of the patient's history (including a description of the pain) and a physical exam. Imaging studies (MRI, CT-myelogram) are used to confirm the diagnosis and will typically show the impingement on the nerve root.

Radicular pain may also be accompanied by numbness and tingling, muscle weakness and loss of specific reflexes. When actual nerve dysfunction is noted, this is termed "radiculopathy".

Area of Pain Distribution. Radicular pain radiates into the lower extremity (thigh, calf, and occasionally the foot) directly along the course of a specific spinal nerve root. The most common symptom of radicular pain is sciatica (pain that radiates along the sciatic nerve - down the back of the thigh and calf into the foot). Sciatica is one of the most common forms of pain caused by compression of a spinal nerve in the low back. It often will be caused by compression of the lower spinal nerve roots (L5 and S1).

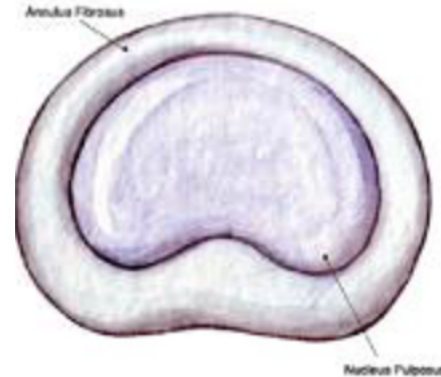
With this condition, the leg pain is typically much worse than the low back pain, and the specific areas of the leg and/or foot that are affected depends on which nerve in the low back is affected. Compression of higher lumbar nerve roots such as L2, L3 and L4 can cause radicular pain into the front of the thigh and the shin.

Spinal Anatomy: Helpful for Understanding Your Lower Back Pain.

The spine is comprised of 33 vertebrae (bones stacked on top of each other in a "building-block" fashion) that have 4 distinct regions: cervical (neck), thoracic (upper/mid back), lumbar (low back), and sacrum (pelvis).

Discs are cushion-like tissues that separate most vertebrae and act as the spine's shock absorbing system. Each disc is comprised of a tough outer ring of fibers called the annulus fibrosus, and a soft gel-like center called the nucleus pulposus.

Each disc is comprised of a tough outer ring of fibers called the annulus fibrosus, and a soft gel-like center called the nucleus pulposus. There are 7 flexible cervical (neck) vertebrae that help to support the head. Twelve thoracic vertebrae attach to ribs. Next, are 5 lumbar vertebrae; they are large and carry the majority of the body weight. The sacral region helps distribute the body weight to the pelvis and hips.



The spinal cord is housed within the protective elements of spinal canal. Spinal nerves branch from the spinal cord and exit the spinal canal through passageways between the vertebral bodies. The passageways are called neuroforamen. Nerves provide sensory (allowing you to touch and feel) and motor information (allowing the muscles to function) to the entire body.

Diagnosis of Lumbar Radiculopathy. A radiculopathy is caused by compression, inflammation and/or injury to a spinal nerve root in the low back. Causes of this type of pain, in the order of prevalence, include:

- **Herniated disc with nerve compression** - by far the most common cause of radiculopathy
- **Foraminal stenosis** (narrowing of the hole through which the spinal nerve exits due to bone spurs or arthritis) – more common in elderly adults
- **Diabetes**
- **Nerve root injuries**
- **Scar tissue from previous spinal surgery** that is affecting the nerve root

Treatment of Lumbar Radiculopathy. It is usually recommended that a course of nonsurgical treatment (such as physical therapy, medications, and selective spinal injections, among others) should be conducted for six to eight weeks. If nonsurgical treatment does not alleviate the pain, decompressive surgery, such as laminectomy and/or discectomy/microdiscectomy, may be recommended. This type of surgery typically provides relief of radicular pain/leg pain for 85% to 90% of patients. For patients with severe leg pain or other serious symptoms such as progressive muscle weakness, this type of surgery may be recommended prior to six weeks of non-surgical treatment. Back surgery for relief of radicular pain (leg pain) is much more reliable than the same surgery for relief of low back pain.

The decision to proceed with surgery is based on severity of leg pain and/or the presence of significant muscle weakness. It is important to note that if definitive nerve compression cannot be documented on an MRI or CT-myelogram, then back surgery is ill advised and unlikely to be successful.

Read more about lumbar radiculopathy at spineuniverse.com and spine-health.com